

Original Article

Efficacy of peptide receptor radionuclide therapy with ¹⁷⁷Lu-octreotate in metastatic pulmonary neuroendocrine tumors: a dual-centre analysis

Amir Sabet¹, Alexander R Haug², Collin Eiden³, Christoph J Auernhammer⁴, Birgit Simon⁵, Peter Bartenstein⁶, Hans J Biersack³, Samer Ezziddin¹

¹Department of Nuclear Medicine, Saarland University, Homburg, Germany; ²Department of Nuclear Medicine, Medical University of Vienna, Austria; Departments of ³Nuclear Medicine, ⁵Radiology, University Hospital, Bonn, Germany; Departments of ⁴Internal Medicine II, ⁶Nuclear Medicine, Ludwig-Maximilians-University, Munich, Germany

Received February 20, 2017; Accepted March 18, 2017; Epub April 15, 2017; Published April 30, 2017

Abstract: There is lack of data on the specific benefit of peptide receptor radionuclide therapy (PRRT) in neuroendocrine tumors (NET) of pulmonary origin. This dual-centre study aimed to assess outcome and toxicity of standardized PRRT with ¹⁷⁷Lu-octreotate in a patient population of advanced pulmonary NET of grade 1-2. We retrospectively assessed 22 consecutively patients treated with 4 intended cycles at 3 monthly intervals (mean activity per cycle 7.8±0.68 GBq). In a median follow-up period of 54 months, no significant nephrotoxicity (≥ grade 3) was observed. Reversible hematotoxicity (grade 3) occurred in 3 patients (13.6%). Treatment response consisted of partial response in 6 (27.3%), stable disease in 9 (40.9%), and progressive disease in 7 (31.8%) patients. Median progression-free survival (PFS) and overall survival (OS) was 27 (95% CI, 9-45) and 42 months (95% CI, 25-59), respectively. High hepatic tumor load (> 50%) and high plasma chromogranin A (> 600 ng/mL) were negative baseline predictors for PFS and OS on univariate analysis, CgA remained significant on multivariate analysis (PFS, P=0.011; OS, P=0.026). Disease progression despite PRRT was associated with shorter survival (median OS 15 vs 53 mo, P<0.001). Despite a higher incidence of treatment failure compared to NET of other origins, the observed substantial and sustained disease stabilization (median PFS of 27 mo, disease control rate of > 2/3 of pts) indicates considerable efficacy of ¹⁷⁷Lu-octreotate in pulmonary NET.

Keywords: Peptide receptor radionuclide therapy, PRRT, ¹⁷⁷Lu-octreotate, pulmonary neuroendocrine tumors, NET

Introduction

Well-differentiated neuroendocrine tumors (NET) of the respiratory tract, i.e. pulmonary NET, are rare malignancies with a serotonin-secreting potential comprising typical (low grade) and atypical (intermediate grade) forms [1]. Patients with metastatic pulmonary NET have generally worse prognosis compared to patients with metastatic NETs of other origins [2]. Furthermore, serotonin-related hypersecretion syndrome with intractable flushing may impact the quality of life in advanced metastatic stages. Treatment with somatostatin analogs is the recommended first-line therapy for unresectable disease with significant anti-secretory and suggested anti-proliferative, but very little

cytoreductive capacities. Effective treatment options for somatostatin analog-refractory patients with uncontrolled functional symptoms or progressive metastatic disease are limited [3, 4]. Various cytotoxic chemotherapy regimens and novel targeted treatments have shown only minor survival benefit with significant toxicity in a considerable portion of patients [5, 6].

Peptide receptor radionuclide therapy (PRRT) with radiolabeled somatostatin analogs is a highly effective treatment for metastatic NET with outstanding treatment tolerance and low toxicity [7-9]. However, data regarding the outcome of pulmonary NET after PRRT have been mainly driven from subgroup analyses of ⁹⁰Y-

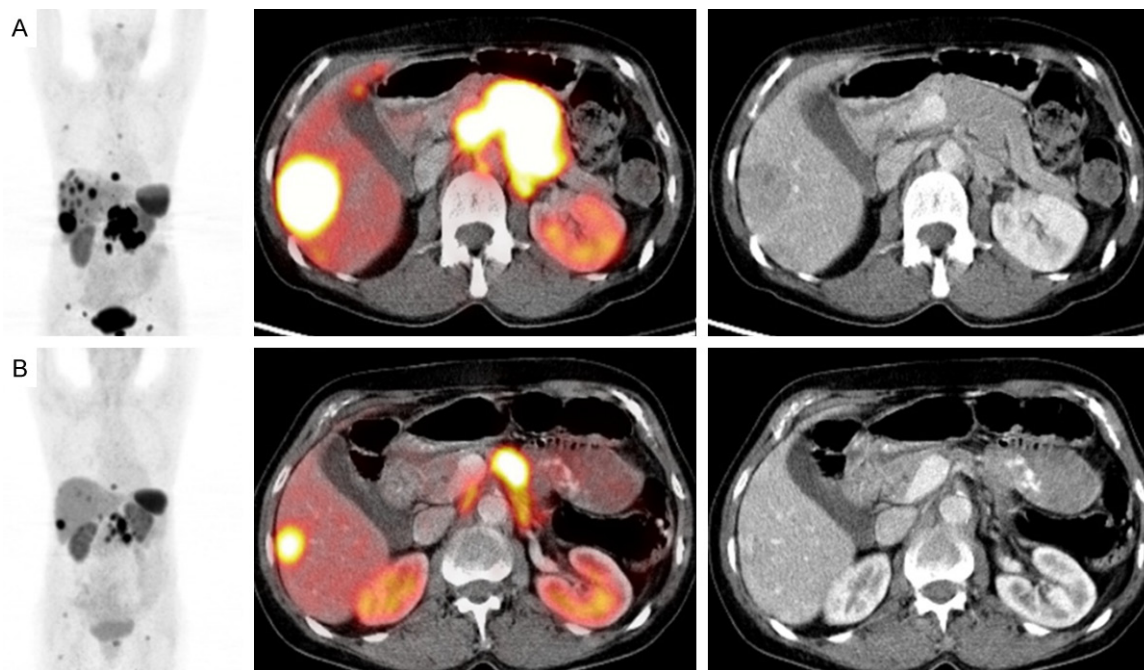


Figure 1. Partial remission illustrated by ^{68}Ga -DOTATOC PET/CT before (A) and 3 months after (B) PRRT in a patient with metastatic pulmonary NET. From left to right: Maximum-intensity-projection PET images (coronal view), fused PET-CT and unfused CT images.

based treatment in NET of different origins [10-15]. The only available report restricted to patients with pulmonary NET has described the outcome in a heterogeneous cohort treated with different compounds (^{177}Lu -octreotate, ^{90}Y -DOTATOC, or the combination) [16]. Although the inter-individual diversity of the treatment schemes hampered accurate comparative analyses, ^{177}Lu -octreotate seemed superior to ^{90}Y -DOTATOC [16]. In this dual-centre evaluation we aimed to assess the outcome and toxicity of PRRT with ^{177}Lu -octreotate in a well-characterized patient population with metastatic well-differentiated pulmonary NET (G1/2) and to explore potential predictors for impaired survival.

Material and methods

We retrospectively analyzed a consecutive cohort of 22 patients (16 men, 6 women; mean age 63 y; range, 42-74) with distant metastatic, unresectable pulmonary NET (stage IV), who underwent PRRT with ^{177}Lu -octreotate [17]. Other inclusion criteria for PRRT were sufficient tumor uptake, i.e. \geq liver uptake on baseline receptor imaging, a glomerular filtration rate of > 30 ml/min/1.73 m², a WBC count ≥ 2000 /mm³, haemoglobin ≥ 8 g/dl and platelets

≥ 75000 /mm³. Treatment decisions were made on a multi-disciplinary basis. 17 patients (77.3%) had documented morphological tumor progression within 12 months before initiation of PRRT. The remaining 5 patients (22.7%) showed uncontrolled functional symptoms despite biotherapy with somatostatin analog medication. 10 patients (45.5%) had functioning tumors with serotonin hypersecretion-related symptoms. 8 patients (36.4%) had extensive hepatic tumor burden, i.e. metastatic replacement of $> 50\%$ of total liver volume according to pretreatment CT/MRI. Metastatic sites included the liver in 19 (86.4%), lymph nodes in 10 (45.5%), bone in 15 (68.2%) and other organs in 6 (27.3%) patients. Previous treatments were comprised of biotherapy (n=16, 72.7%), surgery (n=14, 63.6%), chemotherapy (n=7, 31.8%), and locoregional treatment (n=1, 4.6%). The study was performed in accordance with the Declaration of Helsinki and with national regulations. The local committee on ethics approved this retrospective study, and all patients signed written informed consent.

PRRT

PRRT was performed by standard protocol with administration of a mean activity of 7.8 ± 0.68

PRRT in pulmonary NET

Table 1. Patient characteristics and disease control rate (DCR) according to RECIST 1.1 (SD and PR)

Variable	N	DCR (%)	P
Total	22	15 (68.2)	
Age			
≤ 65 y	14	10 (71.4)	0.512
> 65 y	8	5 (62.5)	
Ki-67 index			
≤ 2%	9	8 (88.9)	0.101
3-20%	13	7 (46.7)	
Hepatic tumor burden			
≤ 50%	14	12 (85.7)	0.052
> 50%	8	3 (35.7)	
Tracer uptake			
≤ grade 2	10	6 (60)	0.652
> grade 2	12	9 (75)	
Progression at baseline			
No	5	4 (80)	1.0
Yes	17	11 (64.7)	
Presence of BMs			
No	7	5 (71.4)	1.0
Yes	15	10 (66.7)	
Functionality			
Non-functional	12	8 (66.7)	1.0
Functional	10	7 (70.0)	
CgA			
≤ 600 ng/ml	7	7 (100)	0.051
> 600 ng/ml	15	8 (53.3)	
NSE			
≤ 15 ng/ml	9	9 (100)	0.017
> 15 ng/ml	13	6 (46.2)	
Typical/Atypical			
Typical	5	4 (80)	1.0
Atypical	17	11 (64.7)	

CgA, chromogranin A; NSE, neuron-specific enolase; BMs, bone metastases.

GBq (211±18 mCi) ¹⁷⁷Lu-octreotate per treatment cycle, aimed at four courses and standard intervals of 3 months (10-14 weeks). The ¹⁷⁷Lu (IDB Holland, Baarle-Nassau, Netherlands) had a specific activity of approximately 100-160 GBq/μmol at the time of administration. The peptide labeling was performed to obtain an apparent specific activity of about 54 GBq/μmol (ratio of activity to the total amount of peptide) [18, 19]. Nephroprotection was implemented with standard amino acid co-infusion according to the Rotterdam protocol (lysine 2.5% and arginine 2.5% in 1 L 0.9% NaCl; infu-

sion of 250 ml/h). As described in previous reports, tumor uptake was classified according to the ¹⁷⁷Lu-octreotate therapy scan of the first PRRT cycle (grade 3, > kidney/spleen; grade 2, > liver; grade 1 ~liver) [20, 21]. This was done to standardize the uptake score for the entire cohort, since some patients underwent somatostatin receptor scintigraphy (eg. Octreoscan) at baseline whereas others received PET imaging with ⁶⁸Ga labeled somatostatin analogs.

Response and toxicity assessment

Hematological parameters were determined prior to each treatment course, in 2-4 weeks intervals between the courses, 8-12 weeks after the last course of PRRT and in 3 monthly intervals in the further follow-up. Toxicity was recorded using the Common Terminology Criteria for Adverse Events v3.0 (CTCAE). Symptomatic response in functioning tumors (n=10) was assessed according to the change in the intensity and frequency of tumor-specific symptoms and was categorized into complete resolution, partial resolution (≥50% reduction), no significant change, and progression of functional symptoms. Restaging was performed 3 months after termination of PRRT. Imaging consisted of CT and/or MRI according to the baseline imaging modality. Follow-up imaging was performed in 6-month intervals after the first restaging. In order to facilitate comparison with other studies, tumor response was classified according to Response Evaluation Criteria in Solid Tumors (RECIST) 1.1.

Survival assessment and statistical analysis

Survival analysis was performed using the Kaplan-Meier curve method. Progression free survival (PFS) was censored at the start of another anti-proliferative treatment. Univariate analysis using the log-rank test was performed for each baseline factor. Multivariate analysis (Cox proportional-hazards model) was performed with those variables showing significance on univariate analysis (log-rank test). All tests were performed with a significance level of P<0.05. The statistical software package SPSS (version 20; SPSS Inc., Chicago/ IL, USA) was used to analyze the data.

Results

22 patients underwent PRRT with ¹⁷⁷Lu-octreotate. The mean cumulative activity per patient

PRRT in pulmonary NET

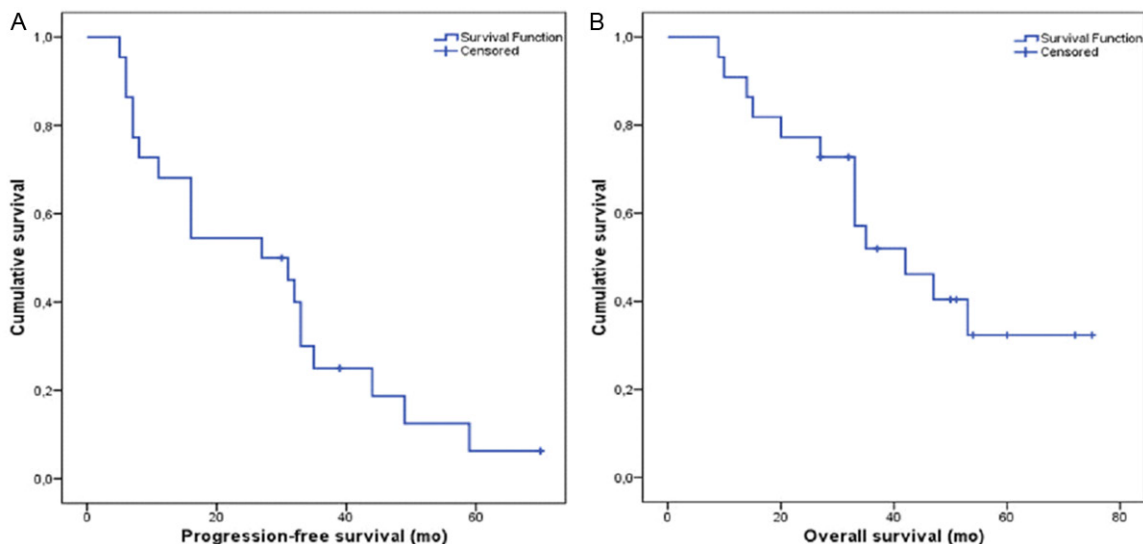


Figure 2. Progression-free (A) and overall (B) survival of the entire patient cohort. The median PFS and OS were 27 months (95% CI, 9-45) and 42 months (95% CI, 25-59), respectively.

was 27.2 ± 5.9 GBq. ^{177}Lu -octreotate administrations were well tolerated without any serious acute adverse events. In 4 patients (18.1%), treatment was stopped after 1 (n=1) or 2 (n=3) cycles because of a documented disease progression. Relevant hematotoxicity (grade 3) was observed 3-10 weeks after at least one of the administrations in 3 patients (13.6%). Blood count values returned to the normal range in all patients, the mean time to complete bone marrow recovery was 19 months after termination of PRRT (range 9-22 months). No significant nephrotoxicity (\geq grade 3) was observed during the follow-up and the mean relative change of GFR was -1% per year. No other relevant toxicities or treatment related deaths were observed. 3 of 10 patients (30%) with functional symptoms had complete and 7 patients (70%) partial resolution of symptoms after treatment. The observed treatment response according to RECIST 1.1 criteria consisted of partial response (PR) in 6 (27.3%), stable disease (SD) in 9 (40.9%), and progressive disease (PD) in 7 (31.8%) patients. An example of a patient with partial response to PRRT is illustrated in **Figure 1**. Disease control rate (DCR) was 68.1% and patients with high hepatic tumor load ($> 50\%$), neuron-specific enolase (NSE) plasma levels > 15 ng/ml and chromogranin A (CgA) plasma levels > 600 ng/ml tended to fail treatment (i.e. progress despite PRRT). The baseline characteristics of the study popu-

lation and the associated DCR are given in **Table 1**.

Median PFS of the entire cohort was 27 months (95% CI, 9-45; **Figure 2A**). The baseline variables associated with shorter PFS in the univariate analysis were CgA > 600 ng/ml ($P=0.006$) and hepatic tumor load $> 50\%$ ($P=0.008$). As shown in **Table 2** high CgA levels remained a significant predictor of earlier progression on multivariate analysis with cox proportional-hazards model: HR 4.4 (95%-CI, 1.4-13.6), $P=0.011$. The median follow-up period was 54 months (range 5-75) and 9 patients were still alive at the time of analysis. The median OS of the entire cohort was 42 months (95% CI, 25-59; **Figure 2B**). Treatment failure, i.e. disease progression despite PRRT, was associated with shorter survival: median OS of 15 mo (95% CI, 12-18) vs. 53 mo (95% CI, N/A), $P<0.001$ (**Figure 3**). The analysis of various baseline factors for potential contribution to OS is shown in **Table 3**. High hepatic tumor load ($P=0.009$) and high CgA levels ($P=0.006$) again were the only risk factors for impaired survival on univariate analysis; CgA > 600 ng/ml remained the only independent predictor of shorter OS on multivariate analysis: (HR 10.4 (95%-CI, 1.3-72.8), $P=0.026$). Kaplan-Meier curves (PFS and OS) of patients stratified by CgA and hepatic tumor burden are shown in **Figure 4**. Survival outcome of patients with typical and atypical tumors were similar ($P=0.323$). Patients with

PRRT in pulmonary NET

Table 2. Uni- and multivariate analyses for potential factors associated with progression-free survival after PRRT

Variable	PFS (95% CI)	Univariate analyses			Multivariate analysis	
		p	HR (95% CI)	p		
Total	27 (9-45)					
Age						
≤ 65 y	23 (5-41)	0.171				
> 65 y	20 (1-72)					
Ki-67 index						
≤ 2%	29 (22-36)	0.276				
> 2%	14 (1-44)					
Hepatic tumor burden						
≤ 50%	8 (5-11)	0.008	1.9 (0.7-5.7)	0.224		
> 50%	32 (29-35)					
Tracer uptake						
≤ grade 2	23 (1-50)	0.703				
> grade 2	26 (1-51)					
Presence of BMs						
No	26 (1-52)	0.446				
Yes	31 (12-50)					
Functionality						
No	31 (6-56)	0.268				
Yes	23 (7-38)					
CgA						
≤ 600 ng/ml	42 (27-56)	0.006	4.4 (1.4-13.6)	0.011		
> 600 ng/ml	16 (6-26)					
NSE						
≤ 15 ng/ml	35 (29-40)	0.088				
> 15 ng/ml	9 (1-17)					
Typical/atypical histology						
Typical	29 (9-49)	0.758				
Atypical	26 (6-47)					

CgA, chromogranin A; NSE, neuron-specific enolase; BMs, bone metastases.

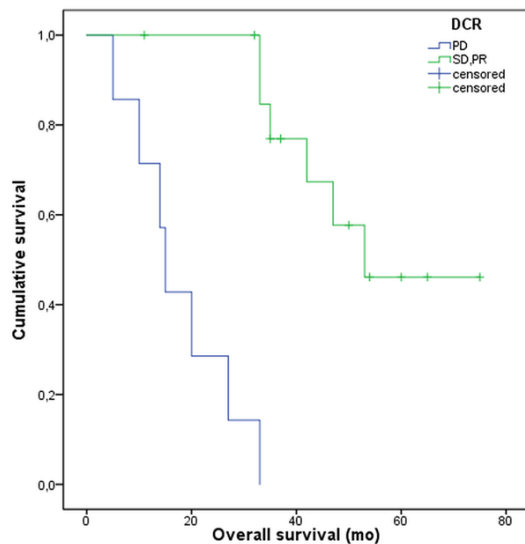


Figure 3. Kaplan-Meier curves illustrating impaired survival of patients failing treatment, i.e. having progressive disease despite PRRT. The median OS of these patients was 15 mo (95% CI, 12-18) vs. 53 mo (95% CI, N/A) in the remaining patients ($P < 0.001$).

documented pretreatment morphologic tumor progression had comparable outcome to that of the remaining patients ($P = 0.570$).

Discussion

This retrospective dual-centre analysis provides efficacy results including explicit progression-free survival and overall survival of PRRT in a patient cohort with advanced well-differentiated pulmonary NET after failing standard treatment with somatostatin analogs. Despite the small patient number ($n = 22$) these findings seem important as they convey the idea on the persistent anti-proliferative activity of ^{177}Lu -octreotate in this specific NET entity at an advanced stage. Achievement of disease-control in more than 2/3 of the patient cohort and long-term stabilization with a median PFS of

27 months is very promising in the context of lacking established treatment alternatives.

Effective treatment options for patients with uncontrolled functionality (carcinoid syndrome) or tumor progression in metastatic pulmonary NET of well-differentiated histology are very limited. Previous investigations with various chemotherapy agents, either as mono- or combined-therapy, were generally discouraging. Best results have been observed after treatment of 13 patients (10 typical and 3 atypical carcinoids) with oral temozolomide achieving PR in 4 (31%) patients and disease stabilization in 8 (62%) patients [22]. Novel targeted treatments with tyrosine-kinase inhibitors such as sunitinib or inhibitor of mammalian target of

PRRT in pulmonary NET

Table 3. Overall survival according to various baseline factors

Variable	OS (95% CI)	Univariate analyses	Multivariate analysis	
		p	HR (95% CI)	P
Total	42 (24-60)			
Age				
≤ 65 y	42 (29-60)	0.883		
> 65 y	33 (N/A)			
Ki-67 index				
≤ 2%	53 (N/A)	0.082		
> 2%	33 (11-55)			
Hepatic tumor burden				
≤ 50%	NR	0.009	2.3 (0.7-8.1)	0.183
> 50%	27 (9-45)			
Tracer uptake				
≤ grade 2	33 (17-49)	0.569		
> grade 2	47 (34-60)			
Progression at baseline*				
Yes	NR	0.570		
No	42 (26-58)			
Bone metastases				
Yes	33 (27-39)	0.710		
No	53 (16-90)			
Functionality				
Non-functional	NR	0.306		
Functional	33 (14-52)			
CgA				
≤ 600 ng/ml	NR	0.006	10.4 (1.3-72.8)	0.026
> 600 ng/ml	33 (23-43)			
NSE				
≤ 15 ng/ml	47 (34-60)	0.266		
> 15 ng/ml	33 (11-55)			
Histology				
Typical	42 (24-60)	0.323		
Atypical	35 (N/A)			

*Documented pretreatment morphologic tumor progression within 12 months before initiation of PRRT; NR, not reached.

rapamycin everolimus were also associated with limited efficacy in patients with non-pancreatic NET [23-26]. In a recent trial on patients with non-functional neuroendocrine tumors of lung or gastrointestinal origin (RADIANT4), everolimus could prolong the PFS in 203 patients including 63 patients with pulmonary NET to less than 15 months [27]. Particular efficacy in pulmonary NET, however, has only been reported in an earlier study on 33 patients and showed a statistically insignificant trend towards longer PFS (13.6 mo) under everolimus

compared to 11 patients who received placebo (5.6 mo) [6].

Data supporting the efficacy of PRRT with radiolabelled somatostatin analogs in metastatic NET is accumulating [20, 21, 28-33] (Table 4). However, the particular benefit in patients with pulmonary NET, especially after ¹⁷⁷Lu-based PRRT, is unclear. In a large study on more than 1000 patients with NET of different origins treated with ⁹⁰Y-DOTATOC, 84 patients with pulmonary NET had a median OS of 40 months (95% CI, 31-50) with no PFS data available [10]. In a retrospective study on 59 patients with advanced NET, 13 patients with pulmonary NET were treated with ⁹⁰Y-DOTATOC and/or ¹⁷⁷Lu-DOTATOC. The reported objective response rate was 62% according to somatostatin receptor imaging; no further information regarding the characteristics and survival outcome of this subgroup was reported [34]. In a study on 16 patients with metastatic foregut NET (n=9 pulmonary, 5 gastric, and 2 of thymic origin) treated with ¹⁷⁷Lu-octreotate 8 patients with pulmonary NET showed at least disease stabilization with a median time to progression of 31 months. Similar to our observations treatment outcome did not differ between atypical and typical pulmonary NETs [12].

The only available study restricted to patients with pulmonary NET has described the outcome in a heterogeneous cohort treated with ¹⁷⁷Lu-octreotate, ⁹⁰Y-DOTATOC, or the combination of both compounds over more than a decade [16]. Less favorable histological characteristics of the patients treated with ⁹⁰Y-DOTATOC and inter-individual diversity of the

PRRT in pulmonary NET

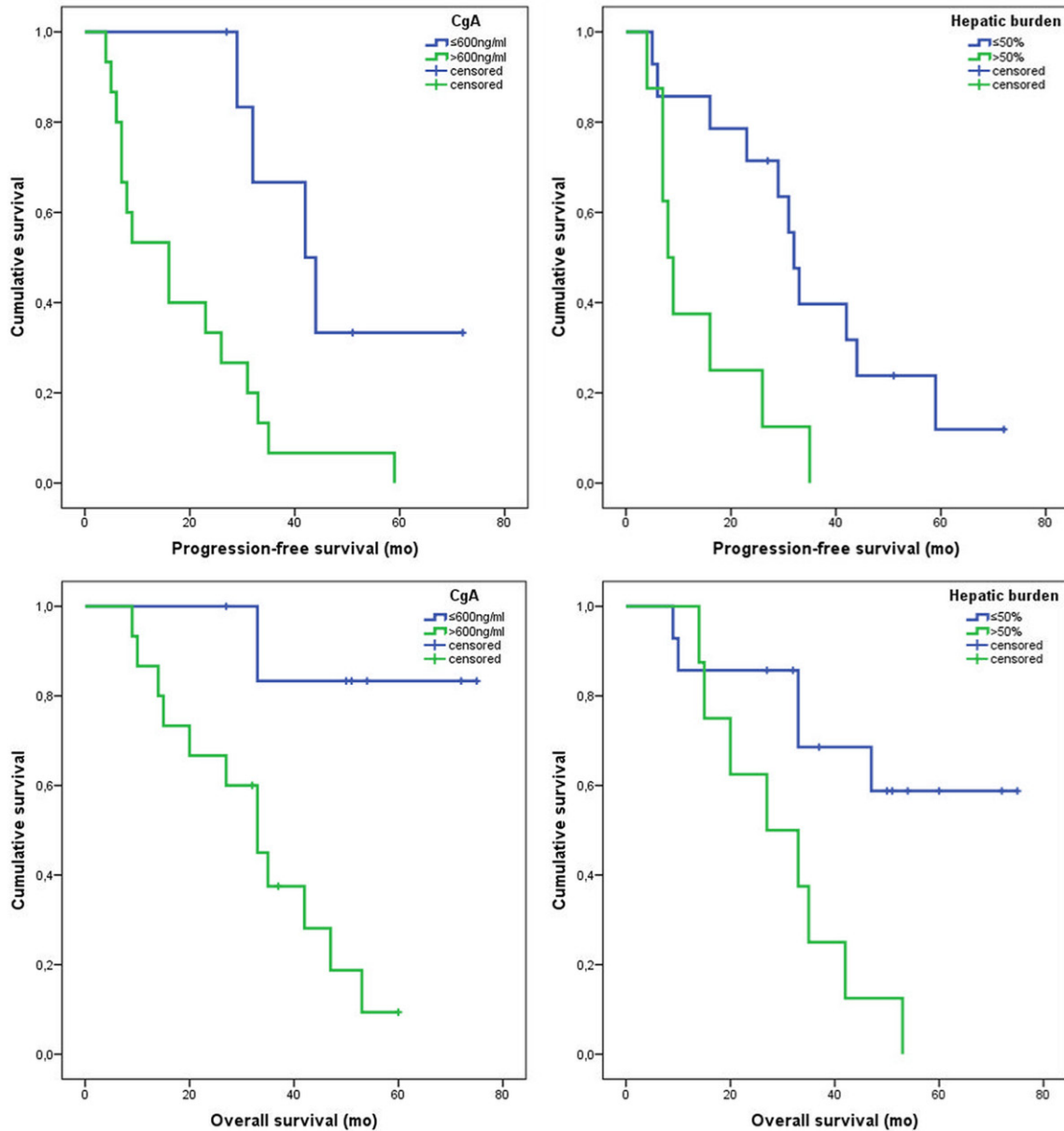


Figure 4. Progression-free survival (above) and overall survival (below) stratified by pre-treatment plasma levels of chromogranin A (CgA, cut-off 600 ng/ml; left) and hepatic tumor burden (liver volume replacement, cut-off 50%; right).

Table 4. Overview of published PRRT results in pulmonary NET

Author	Year/Type	Radioligand	n	ORR (%)	DCR (%)	PFS (mo)	OS (mo)
van Essen	2007/RS	^{177}Lu -DOTATATE	9	55	89	31	NA
Pfeifer	2011/RS	^{90}Y -DOTATOC/ ^{177}Lu -DOTATOC	6	17	67	NA	NA
Imhof	2011/RS	^{90}Y -DOTATOC	84	29	NA	NA	40
Filice	2012/RS	^{90}Y -DOTATOC/ ^{177}Lu -DOTATATE	13	62	85	NA	NA
Mariniello	2016/RS	^{90}Y -DOTATOC/ ^{177}Lu -DOTATATE	114	13	67	28	59*
Sabet	2017/RS	^{177}Lu -DOTATATE	22	27	68	27	42

RS, retrospective study; ORR, objective response rate; DCR, disease control rate; PFS, progression-free survival; OS, overall survival; NA, not available; *Estimated overall survival. Note the lacking survival data from larger reports on primarily mixed NET cohorts.

treatment schemes hampered an accurate comparative analysis of the therapeutic compounds. However, ¹⁷⁷Lu-octreotate seemed superior to ⁹⁰Y-DOTATOC. DCR of 75% was observed in patients treated with ¹⁷⁷Lu-octreotate administered at various therapeutic dosages [16]. Similarly encouraging DCR of 68.2% was seen in our cohort. The objective response rate of 27% also corresponds to the results of the largest published study on PRRT with ¹⁷⁷Lu-octreotate in GEP NET (n=310) by Kwekkeboom et al., reporting an overall response rate of 23% in patients with carcinoid tumors of different origins (n=188) [35]. Consistent with previous reports [36-38] a high level of plasma chromogranin A (> 600 ng/mL) was associated with worsened outcome in our cohort and remained the only independent risk factor for impaired PFS and OS (Tables 2, 3).

Small population size and the retrospective nature inevitably impact on the strength of our conclusions; especially comparisons with historical data should be interpreted with particular caution. We tried to characterize the study population in very detailed manner including all the important variables of potential influence on outcome in order to make comparative considerations possible. Therefore, the potency of therapeutic benefit for the patients seems to be perceptible from the large discrepancy between our findings and the reported data from other modalities.

Disclosure of conflict of interest

None.

Address correspondence to: Samer Ezziddin, Department of Nuclear Medicine, Saarland University, Kirrberger Str.100, Geb. 50, D-66421 Homburg, Germany. Tel: +49 6841 16 22201; Fax: +49 6841 16 24692; E-mail: samer.ezziddin@uks.eu

References

- [1] Naalsund A, Rostad H, Strom EH, Lund MB and Strand TE. Carcinoid lung tumors—incidence, treatment and outcomes: a population-based study. *Eur J Cardiothorac Surg* 2011; 39: 565-569.
- [2] Modlin IM, Lye KD and Kidd M. A 5-decade analysis of 13,715 carcinoid tumors. *Cancer* 2003; 97: 934-959.
- [3] Pavel M, Baudin E, Couvelard A, Krenning E, Öberg K, Steinmüller T, Anlauf M, Wiedenmann B, Salazar R; Barcelona Consensus Conference participants. ENETS Consensus Guidelines for the management of patients with liver and other distant metastases from neuroendocrine neoplasms of foregut, midgut, hindgut, and unknown primary. *Neuroendocrinology* 2012; 95: 157-176.
- [4] Oberg K, Hellman P, Kwekkeboom D, Jelic S; Group EGW. Neuroendocrine bronchial and thymic tumours: ESMO clinical practice guidelines for diagnosis, treatment and follow-up. *Ann Oncol* 2010; 21 Suppl 5: v220-222.
- [5] Kulke MH, Stuart K, Enzinger PC, Ryan DP, Clark JW, Muzikansky A, Vincitore M, Micheline A and Fuchs CS. Phase II study of temozolomide and thalidomide in patients with metastatic neuroendocrine tumors. *J Clin Oncol* 2006; 24: 401-406.
- [6] Fazio N, Granberg D, Grossman A, Saletan S, Klimovsky J, Panneerselvam A and Wolin EM. Everolimus plus octreotide long-acting repeatable in patients with advanced lung neuroendocrine tumors: analysis of the phase 3, randomized, placebo-controlled RADIANT-2 study. *Chest* 2013; 143: 955-962.
- [7] Sabet A, Ezziddin K, Pape UF, Reichman K, Haslerud T, Ahmadzadehfar H, Biersack HJ, Nagarajah J and Ezziddin S. Accurate assessment of long-term nephrotoxicity after peptide receptor radionuclide therapy with (¹⁷⁷)Lu-octreotate. *Eur J Nucl Med Mol Imaging* 2014; 41: 505-510.
- [8] Sabet A, Ezziddin K, Pape UF, Ahmadzadehfar H, Mayer K, Poppel T, Guhlke S, Biersack HJ and Ezziddin S. Long-term hematotoxicity after peptide receptor radionuclide therapy with ¹⁷⁷Lu-octreotate. *J Nucl Med* 2013; 54: 1857-1861.
- [9] Sabet A, Haslerud T, Pape UF, Sabet A, Ahmadzadehfar H, Grunwald F, Guhlke S, Biersack HJ and Ezziddin S. Outcome and toxicity of salvage therapy with ¹⁷⁷Lu-octreotate in patients with metastatic gastroenteropancreatic neuroendocrine tumours. *Eur J Nucl Med Mol Imaging* 2014; 41: 205-210.
- [10] Imhof A, Brunner P, Marincek N, Briel M, Schindler C, Rasch H, Macke HR, Rochlitz C, Muller-Brand J and Walter MA. Response, survival, and long-term toxicity after therapy with the radiolabeled somatostatin analogue [⁹⁰Y-DOTA]-TOC in metastasized neuroendocrine cancers. *J Clin Oncol* 2011; 29: 2416-2423.
- [11] Pfeifer AK, Gregersen T, Gronbaek H, Hansen CP, Muller-Brand J, Herskind Bruun K, Krogh K, Kjaer A and Knigge U. Peptide receptor radionuclide therapy with Y-DOTATOC and (¹⁷⁷)Lu-DOTATOC in advanced neuroendocrine tumors: results from a Danish cohort treated in Swit-

PRRT in pulmonary NET

- erland. *Neuroendocrinology* 2011; 93: 189-196.
- [12] van Essen M, Krenning EP, Bakker WH, de Herder WW, van Aken MO and Kwekkeboom DJ. Peptide receptor radionuclide therapy with ¹⁷⁷Lu-octreotate in patients with foregut carcinoid tumours of bronchial, gastric and thymic origin. *Eur J Nucl Med Mol Imaging* 2007; 34: 1219-1227.
- [13] Bushnell DL Jr, O'Dorisio TM, O'Dorisio MS, Menda Y, Hicks RJ, Van Cutsem E, Baulieu JL, Borson-Chazot F, Anthony L, Benson AB, Oberg K, Grossman AB, Connolly M, Bouterfa H, Li Y, Kacena KA, LaFrance N and Pauwels SA. 90Y-edotreotide for metastatic carcinoid refractory to octreotide. *J Clin Oncol* 2010; 28: 1652-1659.
- [14] Cwikla JB, Sankowski A, Seklecka N, Buscombe JR, Nasierowska-Guttmejer A, Jeziorski KG, Mikolajczak R, Pawlak D, Stepień K and Walecki J. Efficacy of radionuclide treatment DOTATATE Y-90 in patients with progressive metastatic gastroenteropancreatic neuroendocrine carcinomas (GEP-NETs): a phase II study. *Ann Oncol* 2010; 21: 787-794.
- [15] Sowa-Staszczak A, Pach D, Kunikowska J, Krollicki L, Stefanska A, Tomaszuk M, Buziak-Bereza M, Mikolajczak R, Matyja M, Gilis-Januszevska A, Jabrocka-Hybel A, Trofimiuk M and Hubalewska-Dydejczyk A. Efficacy and safety of 90Y-DOTATATE therapy in neuroendocrine tumours. *Endokrynol Pol* 2011; 62: 392-400.
- [16] Mariniello A, Bodei L, Tinelli C, Baio SM, Gilardi L, Colandrea M, Papi S, Valmadre G, Fazio N, Galetta D, Paganelli G and Grana CM. Long-term results of PRRT in advanced bronchopulmonary carcinoid. *Eur J Nucl Med Mol Imaging* 2016; 43: 441-452.
- [17] Rindi G. The ENETS guidelines: the new TNM classification system. *Tumori* 2010; 96: 806-809.
- [18] Breeman WA, De Jong M, Visser TJ, Erion JL and Krenning EP. Optimising conditions for radiolabelling of DOTA-peptides with 90Y, ¹¹¹In and ¹⁷⁷Lu at high specific activities. *Eur J Nucl Med Mol Imaging* 2003; 30: 917-920.
- [19] Breeman WA, van der Wansem K, Bernard BF, van Gameren A, Erion JL, Visser TJ, Krenning EP and de Jong M. The addition of DTPA to [¹⁷⁷Lu-DOTA₀Tyr₃]octreotate prior to administration reduces rat skeleton uptake of radioactivity. *Eur J Nucl Med Mol Imaging* 2003; 30: 312-315.
- [20] Ezziddin S, Khalaf F, Vanezi M, Haslerud T, Mayer K, Al Zreiqat A, Willinek W, Biersack HJ and Sabet A. Outcome of peptide receptor radionuclide therapy with (¹⁷⁷Lu)-octreotate in advanced grade 1/2 pancreatic neuroendocrine tumours. *Eur J Nucl Med Mol Imaging* 2014; 41: 925-933.
- [21] Ezziddin S, Attassi M, Yong-Hing CJ, Ahmadzadehfar H, Willinek W, Grunwald F, Guhlke S, Biersack HJ and Sabet A. Predictors of long-term outcome in patients with well-differentiated gastroenteropancreatic neuroendocrine tumours after peptide receptor radionuclide therapy with ¹⁷⁷Lu-octreotate. *J Nucl Med* 2014; 55: 183-190.
- [22] Ekeblad S, Sundin A, Janson ET, Welin S, Granberg D, Kindmark H, Dunder K, Kozlovacki G, Orlefors H, Sigurd M, Oberg K, Eriksson B and Skogseid B. Temozolomide as monotherapy is effective in treatment of advanced malignant neuroendocrine tumors. *Clin Cancer Res* 2007; 13: 2986-2991.
- [23] Kulke MH, Lenz HJ, Meropol NJ, Posey J, Ryan DP, Picus J, Bergsland E, Stuart K, Tye L, Huang X, Li JZ, Baum CM and Fuchs CS. Activity of sunitinib in patients with advanced neuroendocrine tumors. *J Clin Oncol* 2008; 26: 3403-3410.
- [24] Yao JC, Phan AT, Chang DZ, Wolff RA, Hess K, Gupta S, Jacobs C, Mares JE, Landgraf AN, Rashid A and Meric-Bernstam F. Efficacy of RAD001 (everolimus) and octreotide LAR in advanced low- to intermediate-grade neuroendocrine tumors: results of a phase II study. *J Clin Oncol* 2008; 26: 4311-4318.
- [25] Duran I, Kortmansky J, Singh D, Hirte H, Kocha W, Goss G, Le L, Oza A, Nicklee T, Ho J, Birle D, Pond GR, Arboine D, Dancey J, Aviel-Ronen S, Tsao MS, Hedley D and Siu LL. A phase II clinical and pharmacodynamic study of temsirolimus in advanced neuroendocrine carcinomas. *Br J Cancer* 2006; 95: 1148-1154.
- [26] Pavel ME, Hainsworth JD, Baudin E, Peeters M, Horsch D, Winkler RE, Klimovsky J, Lebwahl D, Jehl V, Wolin EM, Oberg K, Van Cutsem E and Yao JC. Everolimus plus octreotide long-acting repeatable for the treatment of advanced neuroendocrine tumours associated with carcinoid syndrome (RADIANT-2): a randomised, placebo-controlled, phase 3 study. *Lancet* 2011; 378: 2005-2012.
- [27] Yao JC, Fazio N, Singh S, Buzzoni R, Carnaghi C, Wolin E, Tomasek J, Raderer M, Lahner H, Voi M, Pacaud LB, Rouyre N, Sachs C, Valle JW, Fave GD, Van Cutsem E, Tesselaar M, Shimada Y, Oh DY, Strosberg J, Kulke MH, Pavel ME; Rad001 in Advanced Neuroendocrine Tumours FTSG. Everolimus for the treatment of advanced, non-functional neuroendocrine tumours of the lung or gastrointestinal tract (RADIANT-4): a randomised, placebo-controlled, phase 3 study. *Lancet* 2016; 387: 968-77.
- [28] Sabet A, Dautzenberg K, Haslerud T, Aouf A, Sabet A, Simon B, Mayer K, Biersack HJ and

PRRT in pulmonary NET

- Ezziddin S. Specific efficacy of peptide receptor radionuclide therapy with (177)Lu-octreotate in advanced neuroendocrine tumours of the small intestine. *Eur J Nucl Med Mol Imaging* 2015; 42: 1238-1246.
- [29] Bodei L, Kidd M, Paganelli G, Grana CM, Drozdov I, Cremonesi M, Lepensky C, Kwekkeboom DJ, Baum RP, Krenning EP and Modlin IM. Long-term tolerability of PRRT in 807 patients with neuroendocrine tumours: the value and limitations of clinical factors. *Eur J Nucl Med Mol Imaging* 2015; 42: 5-19.
- [30] Ezziddin S, Opitz M, Attassi M, Biermann K, Sabet A, Guhlke S, Brockmann H, Willinek W, Wardelmann E, Biersack HJ and Ahmadzadehfar H. Impact of the Ki-67 proliferation index on response to peptide receptor radionuclide therapy. *Eur J Nucl Med Mol Imaging* 2011; 38: 459-466.
- [31] Sabet A, Khalaf F, Yong-Hing CJ, Sabet A, Haslerud T, Ahmadzadehfar H, Guhlke S, Grunwald F, Biersack HJ and Ezziddin S. Can peptide receptor radionuclide therapy be safely applied in florid bone metastases? A pilot analysis of late stage osseous involvement. *Nuklearmedizin* 2014; 53: 54-59.
- [32] Sabet A, Biersack HJ and Ezziddin S. Advances in peptide receptor radionuclide therapy. *Semin Nucl Med* 2016; 46: 40-46.
- [33] Ezziddin S, Sabet A, Heinemann F, Yong-Hing CJ, Ahmadzadehfar H, Guhlke S, Holler T, Willinek W, Boy C and Biersack HJ. Response and long-term control of bone metastases after peptide receptor radionuclide therapy with (177)Lu-octreotate. *J Nucl Med* 2011; 52: 1197-1203.
- [34] Filice A, Fraternali A, Frasoldati A, Asti M, Grassi E, Massi L, Sollini M, Froio A, Erba PA and Versari A. Radiolabeled somatostatin analogues therapy in advanced neuroendocrine tumors: a single centre experience. *J Oncol* 2012; 2012: 320198.
- [35] Kwekkeboom DJ, de Herder WW, Kam BL, van Eijck CH, van Essen M, Kooij PP, Feelders RA, van Aken MO and Krenning EP. Treatment with the radiolabeled somatostatin analog [177 Lu-DOTA 0,Tyr3]octreotate: toxicity, efficacy, and survival. *J Clin Oncol* 2008; 26: 2124-2130.
- [36] Lawrence B, Gustafsson BI, Kidd M, Pavel M, Svejda B and Modlin IM. The clinical relevance of chromogranin a as a biomarker for gastroenteropancreatic neuroendocrine tumors. *Endocrinol Metab Clin North Am* 2011; 40: 111-134, viii.
- [37] Modlin IM, Gustafsson BI, Moss SF, Pavel M, Tsolakis AV and Kidd M. Chromogranin A--biological function and clinical utility in neuro endocrine tumor disease. *Ann Surg Oncol* 2010; 17: 2427-2443.
- [38] Jensen EH, Kvols L, McLoughlin JM, Lewis JM, Alvarado MD, Yeatman T, Malafa M and Shibata D. Biomarkers predict outcomes following cytoreductive surgery for hepatic metastases from functional carcinoid tumors. *Ann Surg Oncol* 2007; 14: 780-785.